

Research Article

# Arthroscopic-Assisted Reduction and Fixation of a Posterior Cruciate Ligament Avulsion Using Endobutton

Simon M. Thompson<sup>1</sup> and Abdel N. Hassan<sup>2</sup>

<sup>1</sup>Chelsea and Westminster NHS Foundation Trust, 369 Fulham Road, Chelsea, London SW10 9NH, UK

<sup>2</sup>Ashford and St Peter's Hospitals, Guildford Road, Chertsey, Surrey KT16 0PZ, UK

Address correspondence to Simon M. Thompson, s.m.thompson@ic.ac.uk

Received 6 October 2015; Revised 7 November 2016; Accepted 10 November 2016

Copyright © 2016 Simon M. Thompson and Abdel N. Hassan. This is an open access article distributed under the terms of the Creative Commons Attribution License, which permits unrestricted use, distribution, and reproduction in any medium, provided the original work is properly cited.

**Abstract Purpose.** We present a new technique of arthroscopic portal fixation of a posterior cruciate ligament (PCL) avulsion using an Endobutton (Acufex Microsurgical, Inc; Mansfield, MA, USA). **Method.** The PCL bone avulsion was reduced using an anterior cruciate ligament (ACL) aimer guide. An Endobutton is used to maintain and restore the anatomical position of the PCL. The full step-by-step technique is described in this article. **Results.** Anatomical reduction and fixation of a PCL avulsion is achieved via arthroscopic surgery. **Conclusion.** Traditionally open reduction and internal fixation is required using a complex posterior approach. We describe a new method, using arthroscopic surgery without the need for a posterior approach to the knee.

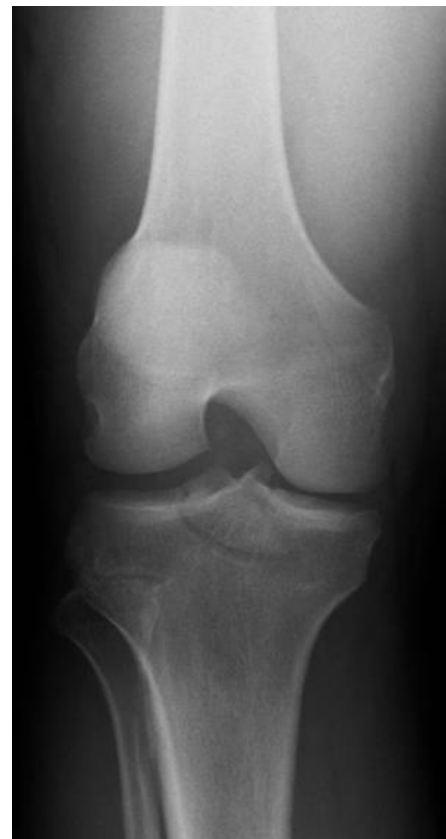**Keywords** arthroscopic; reduction; fixation; posterior cruciate ligament (PCL); avulsion; Endobutton

## 1. Introduction

The posterior cruciate ligament (PCL) prevents posterior translation of the tibia on the femur [1]. Posterior cruciate ligament injuries have in the past been frequently misdiagnosed or missed and, therefore, managed inappropriately, potentially leading to chronic pain and anteromedial knee and patellar degeneration [2,3]. Avulsions of the PCL can be diagnosed on plain radiography, resulting in operative management including open reduction and internal fixation or arthroscopically assisted surgery [4,5,6,7].

Traditionally, open surgery is a difficult procedure necessitating a posterior approach to the knee, which is infrequently performed in most institutions [8,9,10,11]. With intra-articular PCL avulsions, most surgeons would employ the standard posterior approach. We present the arthroscopic portal fixation of a PCL avulsion using an Endobutton (Acufex Microsurgical, Inc; Mansfield, MA, USA) device in a patient with combined anterior cruciate ligament (ACL), medial collateral ligament (MCL), and PCL deficiency. This technique has not been previously reported in the literature.

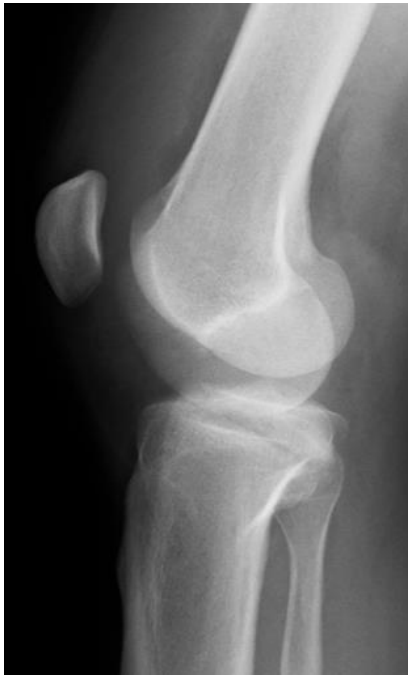The PCL avulsion was large fragment with extension to both the medial and lateral tibial plateau. The PCL was



**Figure 1:** Preoperative anteroposterior radiograph of the right knee demonstrating PCL fracture avulsion.

secured via this technique with MCL reattachment at the same surgery. ACL reconstruction was performed six weeks later.

The patient presented with a massive hemarthrosis, inability to bear weight and gross instability in both the anteroposterior plane and valgus stressing (Figures 1 and 2).



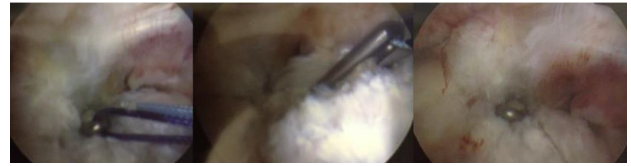
**Figure 2:** Preoperative lateral radiograph of the right knee demonstrating PCL fracture avulsion.

## 2. Method

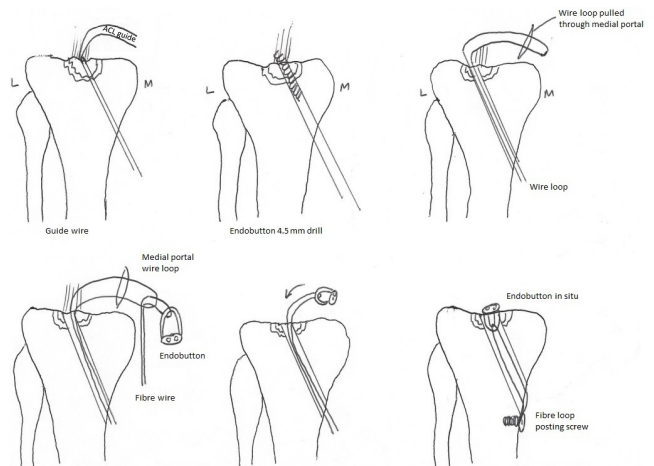
The patient was positioned supine, using a standard arthroscopic set up with foot bolster and side support. The knee was positioned in 90 degrees flexion. Standard arthroscopic lateral and medial portals were established. Intraoperative fluoroscopy was used to confirm bone reduction and passage of guide wires, drills, and the Endobutton.

The PCL bone avulsion was reduced using an ACL aimer guide (Acufex Microsurgical) to maintain position whilst the Endobutton guide wire was drilled through the fragment to maintain position. The 4.5 mm Endobutton drill was then passed over the guide wire through the PCL bone avulsion and the guide wire removed, leaving the drill in situ. An Arthrex flexible suture passer (Arthrex; Naples, FL, USA) was placed retrograde through a cannulated drill into the knee joint. The loop was retrieved using arthroscopic grabbers and brought out through the medial portal.

A loop of FiberStick (Arthrex) was passed through the Endobutton loop; the two limbs of the fibre stick were placed through the suture passer loop and through the 4.5 mm tunnel, and the Endobutton passed into the knee joint through the medial portal. The drill was removed from the knee joint just prior to removing the suture passer. The Endobutton was then pulled down to snug down the bone fragment and restore the anatomical position of the PCL (Figure 3). If assistance was required in toggling the Endobutton, two sutures could be looped through the holes in the Endobutton itself.



**Figure 3:** Endobutton in situ—viewed intraoperatively.



**Figure 4:** The technique is shown step-by-step.

The sutures of fibre wire were then left protruding through the 4.5 mm tunnel and were tied around a posting screw or staple and over-tied. Figure 4 demonstrates the step-by-step technique.

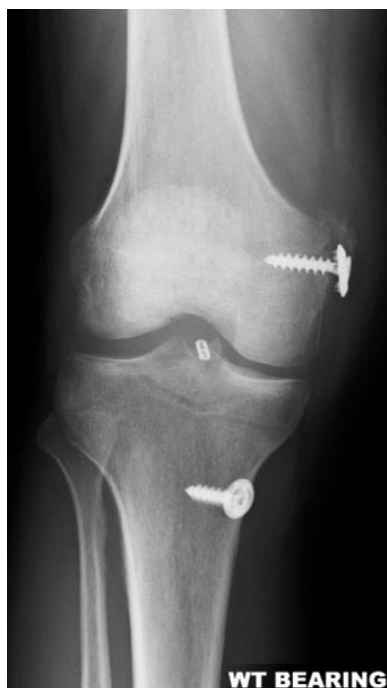## 3. Discussion

The patient made a full recovery back to preoperative function and an absence of PCL sag (Figures 5 and 6). The patient was braced in a range of movement brace 0–90 degrees for two weeks. At six months the knee appeared to be ligamentously stable.

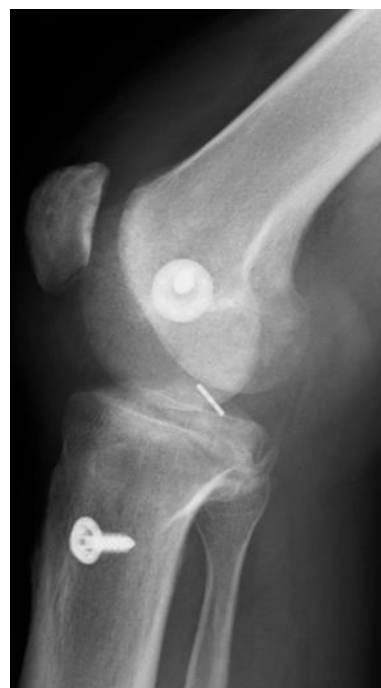The original approach dealing with the popliteal vessels by Abbott was modified to the now standard posterior approach to the knee [12]. Some approaches modified this further but may have included osteotomies of the fibula neck [13,14,15]. Immobilisation of the lower limb was also common place resulting in stiffness and suboptimal results [16,17,18]. The use of functional or range of movement (ROM) brace allowed acceleration of the rehabilitation phase.

There have been reported excellent results in the literature for PCL bony avulsion treated with open reduction and internal fixation, with reported poor functional outcome in patients of bony PCL avulsion treated nonoperatively [2, 17]. This case study has described a new technique to assist in PCL avulsion repair where appropriate.

**Conflict of interest** The authors declare that they have no conflict of interest.



**Figure 5:** Postoperative anteroposterior radiograph of the right knee demonstrating Endobutton position and the associated posting screw for repair of the PCL fracture avulsion. Also shown is the metalwork related to the medial collateral ligament reattachment.



**Figure 6:** Postoperative lateral radiograph of the right knee demonstrating Endobutton position and the associated posting screw for repair of the PCL fracture avulsion. Also shown is the metalwork related to a medial collateral ligament reattachment.

## References

- [1] P. Kannus, J. Bergfeld, M. Järvinen, R. J. Johnson, M. Pope, P. Renström, et al., *Injuries to the posterior cruciate ligament of the knee*, Sports Med, 12 (1991), 110–131.
- [2] M. H. Meyers, *Isolated avulsion of the tibial attachment of the posterior cruciate ligament of the knee*, J Bone Joint Surg Am, 57 (1975), 669–672.
- [3] Y. Tegner and J. Lysholm, *Rating systems in the evaluation of knee ligament injuries*, Clin Orthop Relat Res, 198 (1985), 42–49.
- [4] M. S. Dhillon, H. P. Singh, and O. N. Nagi, *Posterior cruciate ligament avulsion from the tibia: fixation by a posteromedial approach*, Acta Orthop Belg, 69 (2003), 162–167.
- [5] J. Hughston, J. Bowden, J. Andrews, and L. Norwood, *Acute tears of the posterior cruciate ligament. Results of operative treatment*, J Bone Joint Surg Am, 62 (1980), 438–450.
- [6] J. Zhao, Y. He, and J. Wang, *Arthroscopic treatment of acute tibial avulsion fracture of the posterior cruciate ligament with suture fixation technique through Y-shaped bone tunnels*, Arthroscopy, 22 (2006), 172–181.
- [7] T. Torisu, *Isolated avulsion fracture of the tibial attachment of the posterior cruciate ligament*, J Bone Joint Surg Am, 59 (1977), 68–72.
- [8] B. D. Giordano, K. E. DeHaven, and M. D. Maloney, *Acute femoral “peel-off” tears of the posterior cruciate ligament: Technique for arthroscopic anatomical repair*, Am J Orthop, 40 (2011), 226–232.
- [9] S.-Y. Chen, C.-Y. Cheng, S.-S. Chang, M.-C. Tsai, C.-H. Chiu, A. C. Chen, et al., *Arthroscopic suture fixation for avulsion fractures in the tibial attachment of the posterior cruciate ligament*, Arthroscopy, 28 (2012), 1454–1463.
- [10] I.-S. Park and S.-J. Kim, *Arthroscopic fixation of avulsion of the posterior cruciate ligament from femoral insertion*, Arthroscopy, 21 (2005), 1397.e1–1397.e5.
- [11] S. G. Littlejohn and W. B. Geissler, *Arthroscopic repair of a posterior cruciate ligament avulsion*, Arthroscopy, 11 (1995), 235–238.
- [12] L. C. Abbott and W. F. Carpenter, *Surgical approaches to the knee joint*, J Bone Joint Surg Am, 27 (1945), 277–310.
- [13] E. L. Trickey, *Rupture of the posterior cruciate ligament of the knee*, J Bone Joint Surg Br, 50 (1968), 334–341.
- [14] K. Ogata, *Posterior cruciate reconstruction using iliotibial band. Preliminary report of a new procedure*, Arch Orthop Trauma Surg, 101 (1983), 107–110.
- [15] R. T. Burks and J. J. Schaffer, *A simplified approach to the tibial attachment of the posterior cruciate ligament*, Clin Orthop Relat Res, 254 (1990), 216–219.
- [16] F.-Y. Chiu, J.-J. Wu, H.-C. Hsu, L. Lin, and W.-H. Lo, *Management of avulsion injury of the PCL with reattachment*, Injury, 25 (1994), 293–295.
- [17] H. Seitz, I. Schlenz, G. Pajenda, and V. Vecsei, *Tibial avulsion fracture of the posterior cruciate ligament: K-wire or screw fixation? a retrospective study of 26 patients*, Arch Orthop Trauma Surg, 116 (1997), 275–278.
- [18] G. T. Nicandri, E. O. Klineberg, C. J. Wahl, and W. J. Mills, *Treatment of posterior cruciate ligament tibial avulsion fractures through a modified open posterior approach: operative technique and 12- to 48-month outcomes*, J Orthop Trauma, 22 (2008), 317–324.